

# Value of a Novel *Neisseria Meningitidis*-Specific Polymerase Chain Reaction Assay in Skin Biopsy Specimens as a Diagnostic Tool in Chronic Meningococemia

Laurent Parmentier, MD, PhD; Christian Garzoni, MD; Christophe Antille, MD; Laurent Kaiser, MD; Béatrice Ninet, PhD; Luca Borradori, MD

**Background:** Chronic meningococemia (CM) is a diagnostic challenge. Skin lesions are frequent but in most cases nonspecific. Polymerase chain reaction (PCR)-based diagnosis has been validated in blood and cerebrospinal fluid for acute *Neisseria meningitidis* infection, in patients in whom routine microbiologic tests have failed to isolate the bacteria. In 2 patients with CM, we established the diagnosis by a newly developed PCR-based approach performed on skin biopsy specimens.

**Observations:** Two patients presented with fever together with systemic and cutaneous manifestations suggestive of CM. Although findings from blood cultures remained negative, we were able to identify *N meningitidis* in the skin lesions by a newly developed PCR assay. In 1 patient, an *N meningitidis* strain of the same serogroup

was also isolated from a throat swab specimen. Both patients rapidly improved after appropriate antibiotic therapy.

**Conclusions:** To our knowledge, we report the first cases of CM diagnosed by PCR testing on skin biopsy specimens. It is noteworthy that, although *N meningitidis*-specific PCR is highly sensitive in blood and cerebrospinal fluid in acute infections, our observations underscore the usefulness of PCR performed on skin lesions for the diagnosis of chronic *N meningitidis* infections. Whenever possible, this approach should be systematically employed in patients for whom *N meningitidis* infection cannot be confirmed by routine microbiologic investigations.

*Arch Dermatol.* 2008;144(6):770-773

**N** EISSERIA MENINGITIDIS infections are known for their different clinical presentations besides acute meningitis. Among them, subacute or chronic meningococemias (CMs) are usually difficult to diagnose, owing to either misleading or incomplete presentations or to the difficulty in identifying the bacteria in human samples by using routine microscopic and culture techniques. A new generation of technology based on the real-time amplification of the *N meningitidis* genome has been proven sensitive and specific to detect the bacteria in human blood and cerebrospinal fluid (CSF) and characterize its serogroup. This has proven highly valuable when false-negative culture findings are induced by previous blind antibiotherapy or a low bacteria load does not allow detection by direct examination or culture.<sup>1</sup>

Herein, we describe 2 patients presenting with CM. Although findings from all routine microbiologic investigations remained negative, infection with *N meningitidis* was confirmed by a polymerase chain reaction (PCR) assay performed on skin biopsy specimens. The serogroups were also

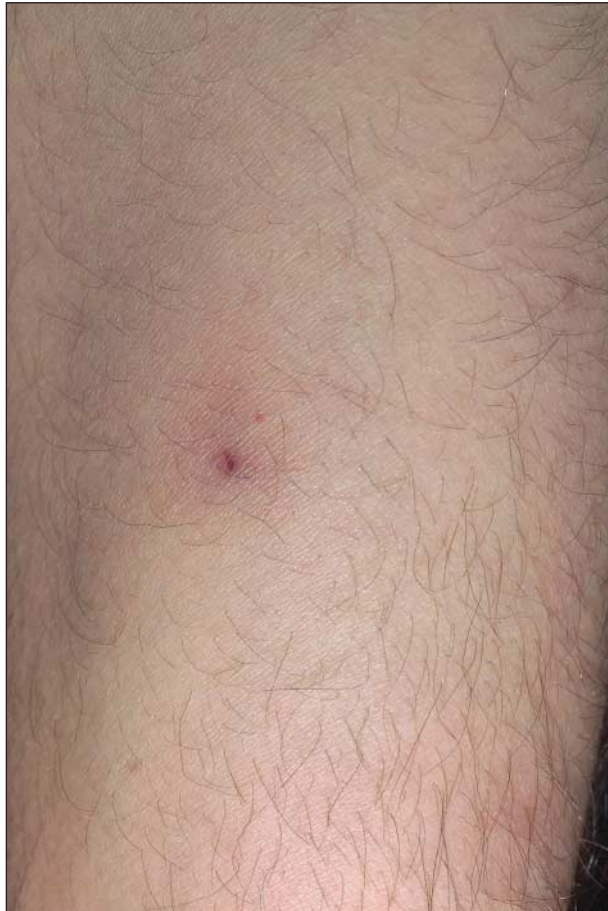defined by an amplification method. We discuss the relevance of skin sampling to help diagnose *N meningitidis* infection and recommend integrating PCR detection to rescue potential false-negative results obtained with the usual microbiologic techniques.

## REPORT OF CASES

### CASE 1

A 23-year-old man was admitted to our clinic for evaluation of fever with body temperature up to 40°C, a 1-week history of gonalgia, a skin rash, and a reduced general condition. The fever had started 4 weeks prior to admission on his return from Morocco. On physical examination, he had arthritis of the right knee. He also had macular erythematous and purpuric lesions disseminated all over his body surface, including 1 sole (**Figure 1**). Laboratory investigations revealed an inflammatory syndrome. Clinical features and settings raised the possibility of a septicemia related to an *N meningitidis* or *Neisseria gonorrhoeae* infection or to Mediterranean spotted fever. Immediately after sampling, empirical an-

**Author Affiliations:** Polyclinique de Dermatologie et Vénérologie (Drs Parmentier, Antille, and Borradori), Service de Maladies Infectieuses (Drs Garzoni and Kaiser), and Laboratoire Central de Bactériologie (Dr Ninet), Hôpital Universitaire de Genève, Genève, Switzerland.

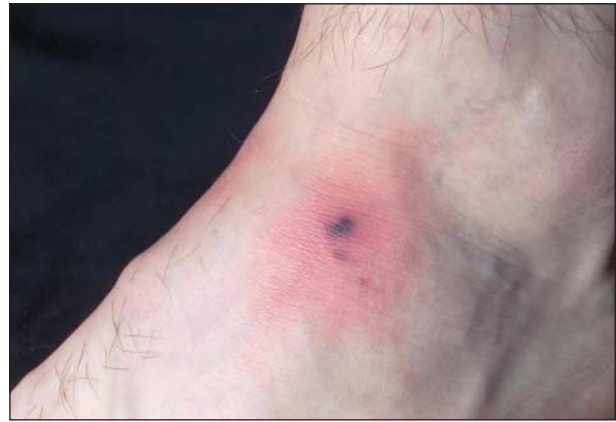

**Figure 1.** Representative example of the skin lesions observed in case 1. A discrete purpuric macule is observed on the forearm.

tibiotherapy combining ceftriaxone sodium, 2 g, and doxycycline, 100 mg, daily was started. The patient's status dramatically improved, and he was clear of symptoms 48 hours later. Both blood and synovial liquid culture findings remained negative. Repeated serologic tests for *Rickettsia conorii* were negative too. Using PCR, we searched for *N meningitidis* on a skin lesion; the test was positive after the patient's discharge from the hospital and thus confirmed our clinical suspicion. Using a PCR-based genogrouping method, we were also able to identify a serogroup B strain. Prophylactic treatment was initiated in all contact subjects.

### CASE 2

A 17-year-old male was admitted with moderate fever associated with pharyngitis and diarrhea of 10 and 3 days' duration, respectively. He also developed a transient skin rash, comprised of several erythematous macular and slightly infiltrated lesions, and a purpuric component on his lower limbs and feet (**Figure 2**). The rest of the physical examination was unremarkable. A mild biologic inflammatory syndrome was found. A septicemia owing to *N gonorrhoeae* or *N meningitidis* was first considered, although viral lesions were also possible. The patient was given ceftriaxone sodium, 1 g, intramuscularly, that resulted in a rapid improvement of all physical signs. Direct examinations and cultures performed on blood and skin biopsy specimens remained



**Figure 2.** Representative example of skin lesions found in case 2, a macular lesion with a central purpuric and necrotic component on the ankle.

sterile for the 2 suspected bacteria. Several viral serologic tests showed no active infection (hepatitis A, B, or C viruses; Epstein-Barr virus; human immunodeficiency virus; adenovirus; enterovirus; echovirus; parvovirus B19). A few days after the patient's discharge from the hospital, the presence of DNA sequences of *N meningitidis* was detected by PCR in the skin biopsy specimen. At the same time, a throat swab culture was positive for *N meningitidis* serogroup C. The serogroup C was also identified by PCR. These findings confirmed the diagnosis of CM. Contact subjects were given prophylactic antibiotherapy.

### METHODS

The *N meningitidis*-specific PCR was performed on a skin biopsy specimen according to the following procedure. A fresh skin punch biopsy specimen was processed immediately after sampling. After a disruption step, small pieces of the biopsy specimen were put in 200  $\mu$ L of a bacterial lysis buffer (Roche Diagnostic Ltd, Basel, Switzerland). A cocktail of enzymes (2  $\mu$ L of LYT 030, the universal lysis kit used for DNA extraction in bacteria) was added and incubated for 30 minutes at 37°C. The DNA was automatically extracted with the MagNa Pure compact system (Roche Diagnostic Ltd). The samples were directly tested with the nucleic acid isolation kit I and the blood protocol. The elution volume was 100  $\mu$ L. Three repetitions of 5  $\mu$ L of extracted DNA were amplified with a real-time PCR TaqMan method using the capsular transport gene (*ctra*) for *N meningitidis*.<sup>2</sup> The serogroups were identified by the same methods but with the sialic acid gene (*siaD*) encoding the polysialyltransferase responsible of sialic acid-containing polysaccharides in strains belonging to serogroups B, C, Y, and W135.<sup>3</sup> The sequences of each primer and probe are described in the **Table**. The positive PCR results for *N meningitidis* genome amplification and the positive PCR result for the serogroup C strain are presented in **Figure 3**.

### COMMENT

Chronic meningococemia is defined as a sepsis caused by *N meningitidis* lasting more than 1 week and presenting without meningeal signs. Most reports, including the first description,<sup>4</sup> underscore the potential prolonged course of the

disease with a spontaneous relapsing evolution. Fever is almost constant, and arthralgias are frequent.<sup>5</sup> The cutaneous manifestations, which are observed in up to 50% of the cases, are variable, including purpuric papules and nod-

ules, and urticarial eruptions.<sup>6,7</sup> Therefore, the clinical presentations of our 2 patients were suggestive of CM. Nevertheless, in the patient presenting with a 10-day course, the disease could also be defined as occult meningococemia.

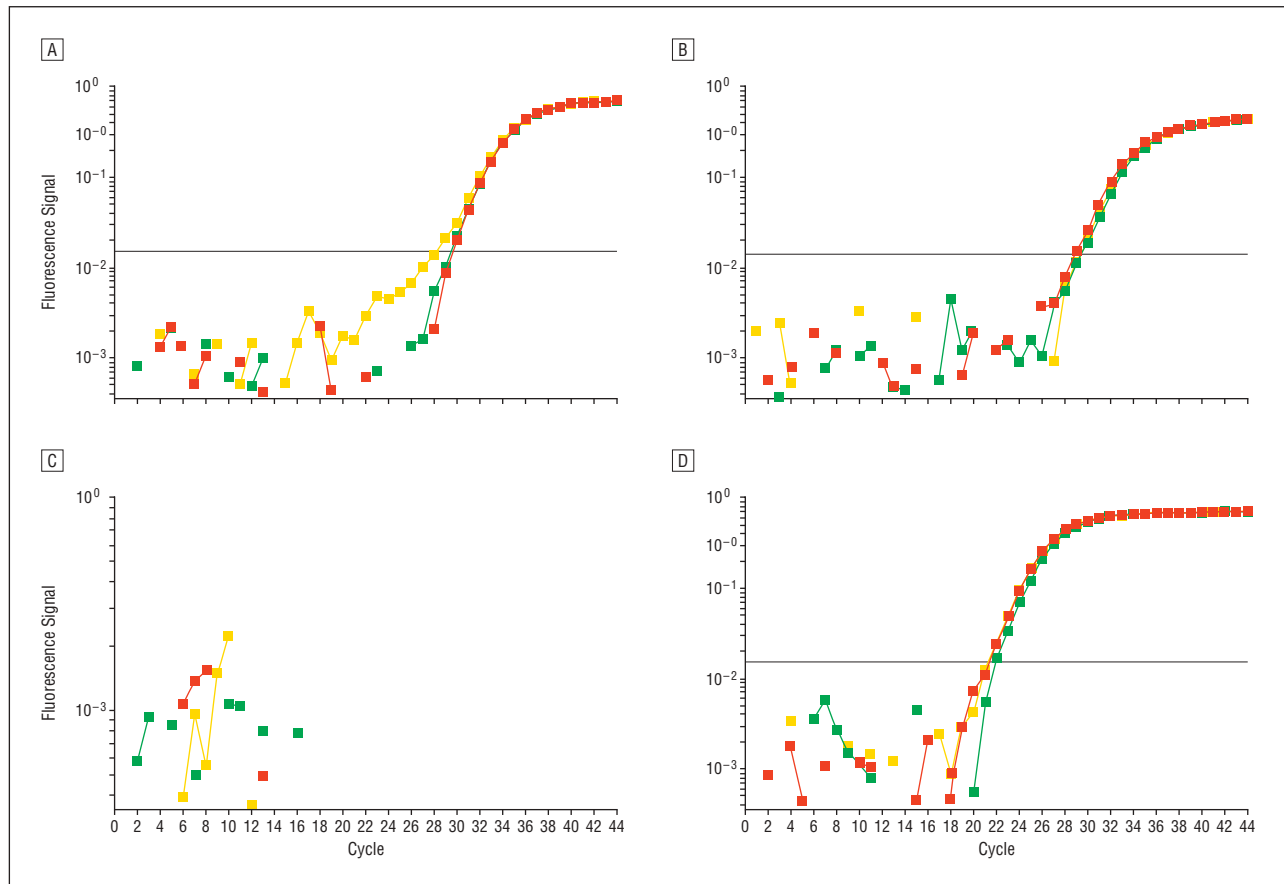
Two points should be emphasized. First, without appropriate treatment, the disease is likely to worsen, affect vital functions, and become life threatening.<sup>8</sup> Carditis and meningitis with fatal outcomes have been described.<sup>8</sup> Second, early diagnosis is often a challenge: false-negative findings from blood cultures are not unusual, and repeated samplings are frequently required. Hence, identification of the responsible bacteria for guiding appropriate antibiotic therapy is frequently delayed or made only after the patient's discharge from the hospital.<sup>9</sup> Therefore, a new, specific, and sensitive microbiologic test allowing for rapid confirmation of the diagnosis is highly desirable and needed.

How can the dermatologist contribute in tackling these issues? Bacterial cultures on skin biopsy samples have been reported to be valuable diagnostic tools in acute *N meningitidis* infections. Rapid diagnosis by Gram staining of needle aspirates or biopsy specimens of skin lesions yielded a sensitivity of 72% in meningococcal sepsis.<sup>10</sup> In another retrospective study,<sup>11</sup> a sensitivity of 80% was obtained for Gram staining smears using material scraped from petechial lesions. Moreover, the test was positive in 17 of 19 patients (89%) with negative findings from blood cul-

**Table. Primers and Probes Used for the Detection and Genogrouping of *Neisseria meningitidis***

TaqMan Real-time PCR for Amplification of	Target Gene	Primers and Probes Sequences
<i>N meningitidis</i>	<i>ctrA</i>	MG610F: 5' GCT GCG GTA GGT GGT TCA A 3' MG720R: 5' TTG TCG CGG ATT TGC AAC TA 3' MG651T: 5' CAT TGC CAC GTG TCA GCT GCA CAT 3' (5' FAM, 3' Tamra)
<i>N meningitidis</i> , serogroup B	<i>siaD</i>	NMB968F: 5' TTA TAG GCC TGG CCT CTA GTT CTT T 3' NMB1096R: 5' TCA TTT CAG TGT TTT CCA CCA TTG 3' NMB998T: 5' ATA CAC CAT TAC TCT CAC CCT CAA CCC AAT GTC 3' (5' FAM, 3' Tamra)
<i>N meningitidis</i> , serogroup C	<i>siaD</i>	NMC1029F: 5' TCT GTC AAT TGG GCA AAT CG 3' NMC1106R: 5' TGC TCT TCA ATT AAA GCG GTG TT 3' NMC1053T: 5' TGA TTC GAT ACA CCA TAC AGC CCA ACA AGA 3' (5' FAM, 3' Tamra)

Abbreviation: PCR, polymerase chain reaction.



**Figure 3.** TaqMan curves obtained after 45 cycles of real-time polymerase chain reaction (PCR) on DNA material yielded from lesional skin from case 2. Each panel shows 3 replicates of each analysis (green, red, and yellow). Each point represents a value of the fluorescent signal at different times of the amplification run. When the measured fluorescent signal exceeds a calculated background threshold identifying amplification of the targeted sequence, a cycle threshold (Ct) value is defined. A, Sample of skin and PCR for *Neisseria meningitidis*. Ct value=29. B, Sample of skin and PCR for *N meningitidis* serogroup C, Ct=29. C, Negative control (no template control), Ct value=45. D, Positive control (100 pg of *N meningitidis* DNA), Ct=21.



tures, allowing reassessment of diagnosis and appropriate treatment. In prospectively studied patients with skin lesions and presumed acute meningococcal diseases, Arend et al<sup>12</sup> obtained a sensitivity of 56% through a combination of Gram stain and culture of skin biopsy specimens. Four of 25 patients with positive findings from skin biopsy specimens had negative blood cultures.

Nevertheless, these studies focused on acute forms of *N meningitidis* infections, whereas in CM, the identification and isolation of the bacteria are usually more challenging. Thus far, sensitivity of skin cultures and Gram stain has not been evaluated in CM. One report<sup>13</sup> of CM has been published in which the bacteria was successfully cultured on skin biopsy specimens only. We report 2 additional observations of CM with negative findings from blood cultures. In both cases, the diagnosis was assessed by the use of a newly developed *N meningitidis*-specific PCR on skin specimens. The PCR was unfortunately not tested in parallel in blood samples. Interestingly, the 2 patients described herein were infected by 2 different strains (serogroup B and serogroup C) that are known to be invasive. In the past decade, the PCR-based diagnosis has proven a valuable tool in the assessment of patients with invasive meningococcal disease.<sup>14</sup> Previously, in meningococcal infections, approximately 90% and 50% of untreated patients had positive CSF or blood culture findings, respectively, a rate decreasing to 5% or less after early antibiotic treatment.<sup>15</sup> Nonculture methods like Gram staining or direct immunodetection of capsular polysaccharide are frequently not sensitive enough to detect the presence of the bacteria.<sup>16</sup> A PCR-based diagnosis, performed either on blood or CSF samples, has been validated as a robust tool to assess the diagnosis in these difficult situations.<sup>17,18</sup> In addition, Fox<sup>1</sup> has already underscored the potential gain in sensitivity in developing PCR methods applied to DNA isolated from additional clinical specimens like skin scrapings or biopsy specimens. Yet, to our knowledge, there have been no reports of successful PCR testing for *N meningitidis* on skin samples.

We used a fluorescence-based PCR method on DNA extracted from lesional skin. The approximate time needed to obtain a definite result is less than 4 hours, with an additional 3 hours needed to determine the serogroup. In 1 of our cases, the concomitant isolation of the same serogroup *N meningitidis* on a throat biopsy sample provided additional evidence for the imputability of the identified bacteria. The failure to detect *N meningitidis* in blood by culture is probably related to the intermittent nature of the bacteremia, whereas in skin biopsy specimens, both dead and alive bacteria are available for PCR detection. Based on our encouraging but preliminary results in 2 patients, it is important that future prospective studies validate the value of *N meningitidis*-specific PCR and compare its sensitivity with both PCR in blood samples and Gram staining of needle aspirates or skin scrapings. Nevertheless, PCR on skin biopsy specimens seems to constitute a valuable tool to validate the diagnosis of CM, at least in forms in which standard diagnostic procedures are known to have a substantial failure rate. Moreover, it is likely that this approach could be employed successfully in acute *N meningitidis* infections. The technique requires less than 3 hours of laboratory work, assuming that the DNA extraction yield is the limiting step. The cost of the reagent is reasonable and

comparable with a standard hemoculture. Therefore, assuming that a skin biopsy is easily performed by a trained physician and that the sample is immediately transferred to the laboratory, we consider it a valuable tool for outpatients when meningococcemia is suspected. To optimally evaluate the potential benefit of using skin biopsy samples as the substrate for PCR, further prospective studies should compare its sensitivity with results obtained in blood and/or CSF.

**Accepted for Publication:** October 21, 2007.

**Correspondence:** Laurent Parmentier, MD, PhD, Polyclinique de Dermatologie et Vénérologie, Hôpital Universitaire de Genève, Rue Micheli-du-Crest 24, 1211 Genève 14, Switzerland (laurent.parmentier@chu-lyon.fr)

**Author Contributions:** Drs Parmentier and Garzoni had full access to all the data in the study and take responsibility for the integrity of the data and the accuracy of the data analysis. *Study concept and design:* Parmentier, Garzoni, Kaiser, and Borradori. *Acquisition of data:* Garzoni, Antille, Ninet, and Borradori. *Analysis and interpretation of data:* Parmentier, Garzoni, Antille, Kaiser, and Ninet. *Drafting of the manuscript:* Parmentier, Garzoni, Antille, and Ninet. *Critical revision of the manuscript for important intellectual content:* Parmentier, Kaiser, and Borradori. *Administrative, technical, and material support:* Antille and Ninet. *Study supervision:* Parmentier, Garzoni, and Borradori.

**Financial Disclosure:** None reported.

## REFERENCES

1. Fox AJ. Nucleic acid technologies and meningococcal infection. *J Infect.* 2001;42(2):100-103.
2. Corless CE, Guiver M, Borrow R, et al. Simultaneous detection of *Neisseria meningitidis*, *Haemophilus influenzae*, and *Streptococcus pneumoniae* in suspected cases of meningitis and septicaemia using real-time PCR. *J Clin Microbiol.* 2001;39(4):1553-1558.
3. Mölling P, Jacobsson S, Bäckman A, et al. Direct and rapid identification and genogrouping of meningococci and porA amplification by LightCycler PCR. *J Clin Microbiol.* 2002;40(12):4531-4535.
4. Benoit FL. Chronic meningococemia. *Am J Med.* 1963;35:103-112.
5. Giamarellos-Bourboulis EJ, Grecka P, Petrikos GL, et al. Primary meningococcal arthritis: case report and review. *Clin Exp Rheumatol.* 2002;20(4):553-554.
6. Harwood CA, Stevens JC, Orton D, et al. Chronic meningococcaemia: a forgotten meningococcal disease. *Br J Dermatol.* 2005;153(3):669-671.
7. Carré D, Domp Martin A, Sannier K, et al. Chronic meningococemia. *Ann Dermatol Venereol.* 2005;132(4):355-358.
8. Kuppermann N, Malley R, Inkelis SH, et al. Clinical and hematologic features do not reliably identify children with unsuspected meningococcal disease. *Pediatrics.* 1999;103(2):E20.
9. Kuppermann N. Occult bacteremia in young febrile children. *Pediatr Clin North Am.* 1999;46(6):1073-1109.
10. van Deuren M, van Ijke BJ, Koopman RJ, et al. Rapid diagnosis of acute meningococcal infections by needle aspiration or biopsy of skin lesions. *BMJ.* 1993;306(6887):1229-1232.
11. Periappuram M, Taylor MR, Keane CT. Rapid detection of meningococci from petechiae in acute meningococcal infection. *J Infect.* 1995;31(3):201-203.
12. Arend SM, Lavrijsen AP, Kuijken I, et al. Prospective controlled study of the diagnostic value of skin biopsy in patients with presumed meningococcal disease. *Eur J Clin Microbiol Infect Dis.* 2006;25(10):643-649.
13. Texereau M, Roblot P, Dumars A, et al. The usefulness of skin culture in the diagnosis of chronic meningococcaemia. *J Intern Med.* 1997;242(6):519-520.
14. Ni H, Knight AI, Cartwright K, et al. Polymerase chain reaction for diagnosis of meningococcal meningitis. *Lancet.* 1992;340(8833):1432-1434.
15. Cartwright K, Reilly S, White D, et al. Early treatment with parenteral penicillin in meningococcal disease. *BMJ.* 1992;305(6846):143-147.
16. Zollinger WD, Boslego J. Immunologic methods for the diagnosis of infection by Gram-negative cocci. In: Rose NR, DeMacario EC, Fahey JL, Friedman H, Pen GM, eds. *Manual of Clinical Laboratory Immunology*. Washington, DC: American Society for Microbiology; 1992:440-451.
17. Clarke SC. Detection of *Neisseria meningitidis*, *Streptococcus pneumoniae*, and *Haemophilus influenzae* in blood and cerebrospinal fluid using fluorescence-based PCR. *Methods Mol Biol.* 2006;345:69-77.
18. Fox AJ, Taha M-K, Vogel U. Standardized nonculture techniques recommended for European reference laboratories. *FEMS Microbiol Rev.* 2007;31(1):84-88.

portant intellectual content: Lee, Kossard, and McGrath. Administrative, technical, or material support: Lee. Study supervision: Kossard and McGrath.

Financial Disclosure: None reported.

Funding/Support: Dr Lee received a Health Manpower Development Programme grant from the National Healthcare Group and Ministry of Health, Singapore, for her fellowship in dermatopathology at the Skin and Cancer Foundation Australia.

Role of the Sponsor: The sponsor had no role in the design and conduct of the study; in the collection, analysis, and interpretation of data; or in the preparation, review, or approval of the manuscript.

## REFERENCES

1. Carlson JA, Ng BT, Chen KR. Cutaneous vasculitis update: diagnostic criteria, classification, epidemiology, etiology, pathogenesis, evaluation and prognosis. *Am J Dermatopathol*. 2005;27(6):504-528.
2. Kossard S. Defining lymphocytic vasculitis. *Australas J Dermatol*. 2000;41(3):149-155.
3. Carlson JA, Mihm MC Jr, LeBoit PE. Cutaneous lymphocytic vasculitis: a definition, a review, and a proposed classification. *Semin Diagn Pathol*. 1996;13(1):72-90.
4. Jennette JC, Falk RJ, Andrassy K, et al. Nomenclature of systemic vasculitides: proposal of an international consensus conference. *Arthritis Rheum*. 1994;37(2):187-192.
5. Hunder GG, Arend WP, Bloch DA, et al. The American College of Rheumatology 1990 criteria for the classification of vasculitis: introduction. *Arthritis Rheum*. 1990;33(8):1065-1067.
6. Lightfoot RW Jr, Michel BA, Bloch DA, et al. The American College of Rheumatology 1990 criteria for the classification of polyarteritis nodosa. *Arthritis Rheum*. 1990;33(8):1088-1093.
7. Daoud MS, Hutton KP, Gibson LE. Cutaneous periarteritis nodosa: a clinicopathological study of 79 cases. *Br J Dermatol*. 1997;136(5):706-713.
8. Weedon D. The vasculopathic reaction pattern. In: *Skin Pathology*. 2nd ed. Edinburgh, Scotland: Churchill Livingstone; 2002:221-278.
9. McKee PH, Calonje E, Granter S, eds. *Vascular diseases*. In: *Pathology of the Skin: With Clinical Correlations*. 3rd ed. Philadelphia, PA: Elsevier Mosby; 2005:709-773.
10. Maessen-Visch MB, Koedam MI, Hamulyak K, Neumann HA. Atrophie blanche. *Int J Dermatol*. 1999;38(3):161-172.
11. Bard JW, Winkelmann RK. Livedo vasculitis: segmental hyalinizing vasculitis of the dermis. *Arch Dermatol*. 1967;96(5):489-499.
12. Calamia KT, Balabanova M, Perniciaro C, Walsh JS. Livedo (livedoid) vasculitis and the factor V Leiden mutation: additional evidence for abnormal coagulation. *J Am Acad Dermatol*. 2002;46(1):133-137.
13. Pizzo SV, Murray JC, Gonias SL. Atrophie blanche: a disorder associated with defective release of tissue plasminogen activator. *Arch Pathol Lab Med*. 1986;110(6):517-519.
14. Hairston BR, Davis MD, Pittelkow MR, Ahmed I. Livedoid vasculopathy: further evidence for procoagulant pathogenesis. *Arch Dermatol*. 2006;142(11):1413-1418.
15. Pierangeli SS, Chen PP, Gonzalez EB. Antiphospholipid antibodies and the antiphospholipid syndrome: an update on treatment and pathogenic mechanisms. *Curr Opin Hematol*. 2006;13(5):366-375.
16. Miyakis S, Lockshin MD, Atsumi T, et al. International consensus statement on an update of the classification criteria for definite antiphospholipid syndrome (APS). *J Thromb Haemost*. 2006;4(2):295-306.
17. Alegre VA, Winkelmann RK. Histopathologic and immunofluorescence study of skin lesions associated with circulating lupus anticoagulant. *J Am Acad Dermatol*. 1988;19(1, pt 1):117-124.
18. Lamprecht P, deGroot K, Schnabel A, Csernok E, Liedvogel B, Gross WL. Anticardiolipin antibodies and antibodies to  $\beta_2$ -glycoprotein I in patients with Wegener's granulomatosis. *Rheumatology (Oxford)*. 2000;39(5):568-570.
19. Manna R, Latteri M, Cristiano G, Todaro L, Scuderi F, Gasbarrini G. Anticardiolipin antibodies in giant cell arteritis and polymyalgia rheumatica: a study of 40 cases. *Br J Rheumatol*. 1998;37(2):208-210.
20. Dasgupta B, Almond MK, Tanqueray A. Polyarteritis nodosa and the antiphospholipid syndrome. *Br J Rheumatol*. 1997;36(11):1210-1212.
21. Ferenczi K, Chang T, Camouse M, et al. A case of Churg-Strauss syndrome associated with antiphospholipid antibodies. *J Am Acad Dermatol*. 2007;56(4):701-704.
22. Norden DK, Ostrov BE, Shafritz AB, Von Feldt JM. Vasculitis associated with antiphospholipid syndrome. *Semin Arthritis Rheum*. 1995;24(4):273-281.
23. Rees JD, Lanca S, Marques PV, et al. Prevalence of the antiphospholipid syndrome in primary systemic vasculitis. *Ann Rheum Dis*. 2006;65(1):109-111.
24. Levine JS, Branch DW, Rauch J. The antiphospholipid syndrome. *N Engl J Med*. 2002;346(10):752-763.
25. Fein H, Sheth AP, Mutasim DF. Cutaneous arteritis presenting with hyperpigmented macules: macular arteritis. *J Am Acad Dermatol*. 2003;49(3):519-522.
26. Sadahira C, Yoshida T, Matsuoka Y, Takai I, Noda M, Kubota Y. Macular arteritis in Japanese patients. *J Am Acad Dermatol*. 2005;52(2):364-366.
27. Chen KR, Sakamoto M, Ikemoto K, Abe R, Shimizu H. Granulomatous arteritis in cutaneous lesions of Churg-Strauss syndrome. *J Cutan Pathol*. 2007;34(4):330-337.
28. Carlson JA, Chen KR. Cutaneous vasculitis update: neutrophilic muscular vessel and eosinophilic, granulomatous, and lymphocytic vasculitis syndromes. *Am J Dermatopathol*. 2007;29(1):32-43.
29. Harvell JD, Williford PL, White WL. Benign cutaneous Degos' disease: a case report with emphasis on histopathology as papules chronologically evolve. *Am J Dermatopathol*. 2001;23(2):116-123.
30. Soter NA, Murphy GF, Mihm MC Jr. Lymphocytes and necrosis of the cutaneous microvasculature in malignant atrophic papulosis: a refined light microscope study. *J Am Acad Dermatol*. 1982;7(5):620-630.
31. Zelger B, Sepp N, Schmid KW, Hintner H, Klein G, Fritsch PO. Life history of cutaneous vascular lesions in Sneddon's syndrome. *Hum Pathol*. 1992;23(6):668-675.

## Correction

**Error in Author Contributions.** In the Observation by Parmentier et al titled "Value of a Novel *Neisseria meningitidis*-Specific Polymerase Chain Reaction Assay in Skin Biopsy Specimens as a Diagnostic Tool in Chronic Meningococemia," published in the June issue of the *Archives* (2008;144[6]:770-773), the Author Contributions paragraph should have included the sentence, "Drs Parmentier and Garzoni equally contributed to the work."